

DRASKO SIMOVIC, M.D.

Carpal Tunnel Syndrome

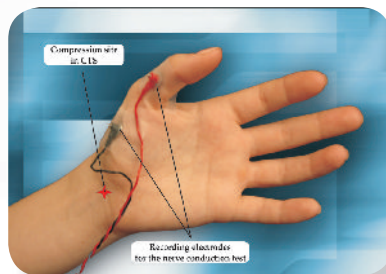
History

Carpal tunnel syndrome (CTS) is the most frequently encountered mononeuropathy in the clinical practice. Although now a well recognized entity, it took almost 100 years from the initial observations until the pathophysiology of the disorder was finally accepted as a median nerve compression at the wrist. Sir James Paget (1854) was the first to describe the clinical features of CTS.

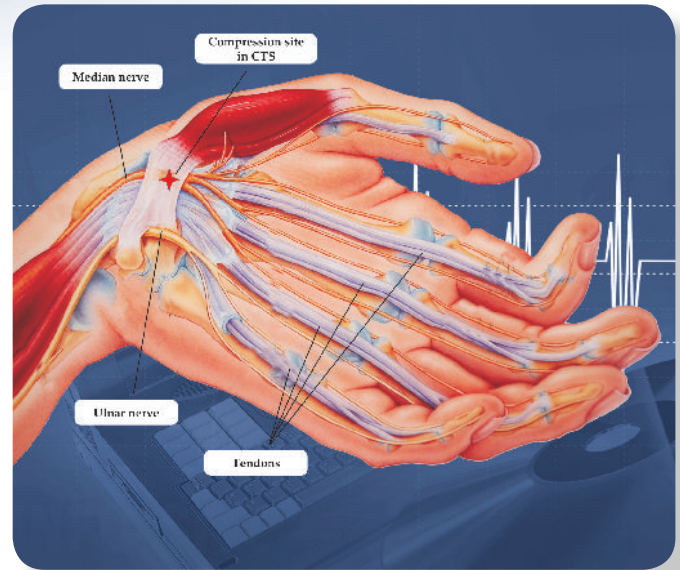
A landmark article of Marie and Foix (1913) provided the first comprehensive clinical and pathologic assessment of a non-traumatic median nerve lesion at the wrist. Despite these correct observations of Marie and Foix, the clinical symptoms we now understand to represent CTS were generally judged secondary to proximal nerve compression. The most common treatment option in first four decades of the century was a cervical rib excision. Influential physicians such as F. Buzzard (1907), S.A. Kinnier Wilson (1913) and P. Sargent (1921) popularized this approach, concluding that a cervical rib, in patients with aberrant innervation of the opponens pollicis and abductor pollicis brevis by the seventh cervical root, could compress the C7 root and produce thenar atrophy and sensory changes in the first three fingers. It was the clinical failure of the cervical rib resections that led to a fundamental reconsideration of the pathophysiology of the disorder.

In the 1950's, G. Phalen published a series of landmark articles solidifying and further defining CTS as a clinical syndrome resulting from median nerve compression at the wrist. He confirmed the usefulness of Tinel's sign as the quintessential maneuver to provoke sensory phenomena in CTS. Finally, he concluded that transection of the carpal ligament could decompress the nerve sufficiently to restore its normal function. It took more than 4 decades from the initial recognition that CTS was caused by median nerve compression at the wrist until transection of the transverse carpal ligament became the main therapeutic option for CTS.

Simovic & Weinberg
Archives of Neurology
57:754-755



Median nerve motor
nerve conduction study



Hand anatomy

Case Report

A 58 y.o. mechanic presents with a severe wrist pain and tingling in his fingers with sparing of the 5th finger. His nocturnal symptoms are very prominent and shaking of the hands is decreasing symptoms. Some neck discomfort and stiffness have been present for several years with occasional radiation to the arms.

Physical examination showed weakness of the bilateral APB muscles and a decreased sensation in the thumb, index and middle fingers. Percussion of the median nerve at the wrists provoked tingling in the index and middle fingers (Tinel's sign).

Continued on page 2

CAPE COD
6 Main Street
Hyannis, MA 02601
Tel: 508-775-2600

DRASKO SIMOVIC, M.D.
Board Certified in: Neurology, Clinical Neurophysiology,
Electrodiagnostic Medicine, Disability Analysis

LAWRENCE
25 Marston Street # 208
Lawrence, MA 01841
Tel: 978-687-2586

NEUROMUSCULAR REVIEW

EMG LABORATORY

"COMMITTED TO EXCELLENCE IN NEURODIAGNOSTICS"

CTS Quantitative Screening Scale

Clinical diagnostic parameters:	Points
1) pain in the hand, forearm or upper arm	1
2) paresthesias or numbness in the hand	1
3) weakness or clumsiness in the hand	1
4) occurrence of the above symptoms isolated to median nerve distribution	4
5) symptoms provoked by sleep	2
6) symptoms provoked by sustained hand/arm position or repetitive action of the hand and wrist	2
7) symptoms decreased with a change in hand position	2
8) symptoms decreased with hand shaking	2
9) presence of Tinel's or Phalen's sign	5
10) sensory loss in the median nerve distribution	5
11) weakness or atrophy of thenar muscles	5
TOTAL SCORE:	

Case report continued:

What does the clinical picture suggest and what differential diagnosis must be considered?

Carpal Tunnel Syndrome is the most likely diagnosis. Alternative options would be proximal median nerve lesion (Pronator Teres Syndrome or ligament of Struthers compression) or a C6 root affliction.

How may an EMG help?

The role of the EMG is to evaluate for presence and severity of CTS, rule out proximal median nerve lesion, evaluate for a cervical radiculopathy and screen for a diffuse condition such as polyneuropathy.

Newsletter courtesy of:

EMG Laboratory
Drasko Simovic, M.D.

Lawrence: 978-687-2486

Hyannis: 978-775-2600

www.emglaboratory.com

Comments or suggestions?

info@emglaboratory.com

What did the EMG show?

It showed bilaterally prolonged medial motor distal latency with a decreased bilateral median sensory amplitude and a prolonged median sensory and mixed nerve peak latency. All other nerve conduction studies were normal. EMG showed abnormal recruitment pattern in bilateral APB muscles and no evidence of active or chronic neurogenic changes in bilateral Deltoid, Biceps, Triceps, Pronator Teres and FDI muscles.

Which conditions could be associated with CTS?

Diabetes mellitus, rheumatoid arthritis, gout, amyloidosis, myxedema, multiple myeloma, pregnancy, hemodialysis, SLE, scleroderma, acromegaly, repetitive wrist motion stress injury, hypothyroidism, ganglion, sarcoid and previous radius fracture. Most cases are idiopathic.

Treatment:

Depending on the clinical and electrophysiologic severity, conservative options (splinting, anti-inflammatory medications or wrist steroid injections) may be tried first. If no improvement is seen, a surgical approach (open or endoscopic) may be necessary. Surgical CT release was shown to have a high success rate.

CTS Scale Grade

CTS scale grade	Total points
Unlikely CTS	1-6
Possible CTS	7-8
Probable CTS	9-30

Quantitative CTS Screening Scale

CTS Scale was developed in order to assist in screening patients with a potential CTS. The positive predictive value (PPV) for the total score was 79.2% with negative predictive value (NPV) of 91.7%. Using a discriminant function analysis the best linear function for predicting the CTS was: $6.8 + 4.7^* \text{ median sensory loss} + 3.95^* \text{ hand posture change symptom amelioration} + 3.8^* \text{ sleep symptoms} + 2.6^* \text{ thenar weakness} + 2.6^* \text{ Tinel's/Phalen's sign} + 2.5^* \text{ repetitive motion symptom aggravation}$. The new linear function score correlates well with the total scale points ($P < 0.001$; $r = 0.79$) with a PPV = 91.7% and a NPV = 98.2%.

Simovic & Weinberg, Neurology; 50 (4); A302