

DRASKO SIMOVIC, M.D.

Ulnar Neuropathy

The ulnar nerve is derived from C8 and T1 roots then passes through the lower trunk and medial cord of the brachial plexus. Just above the elbow it enters the ulnar groove, passes through the cubital tunnel and exits 4 – 6 cm distal to the medial epicondyle. It proceeds to the wrist and enters the hand through the Guyon's canal. It innervates the majority of the intrinsic hand muscles, the palmar surface of the hand, the ulnar half of the ring finger and the whole fifth finger.

Ulnar entrapment at the elbow

It is the second most common nerve entrapment in adults. Etiology includes:

- Extrinsic compression
- Elbow fractures
- Osteoarthritis
- Rheumatoid Arthritis
- Habitual elbow flexion in sleep
- Occupational repetitive flexion/extension
- Hereditary neuropathy with liability to pressure palsy
- Diabetes

Symptomatology:

Patients usually present with intermittent sensory disturbance in the fourth and fifth fingers, pain in the area of medial epicondyle, clumsiness of the hand, weakness of the intrinsic hand muscles, inability to adduct the fifth finger, and eventually atrophy of the hand muscles excluding thenar muscles.

Sensory examination usually reveals decreased sensation in the ulnar aspect of the fourth finger and the whole fifth finger. Motor examination reveals weakness and atrophy

of the dorsal interosseous muscles. Eventually, clawing of the hand is seen. When attempting to pinch a paper between the thumb and index finger, the patient flexes the thumb interphalangeal joint (Froment's sign). This is due to the use of the median innervated flexor pollicis longus muscle, instead of weak ulnar innervated adductor pollicis muscle. Positive Tinel's sign may be seen with percussion of the ulnar nerve at the ulnar groove.

Electrodiagnostic studies:

NCS/EMG is critical in diagnosis, in order to establish the exact location of the lesion, type and severity of the nerve injury (demyelinating versus axonal injury), and exclude other conditions that are in a differential diagnosis.

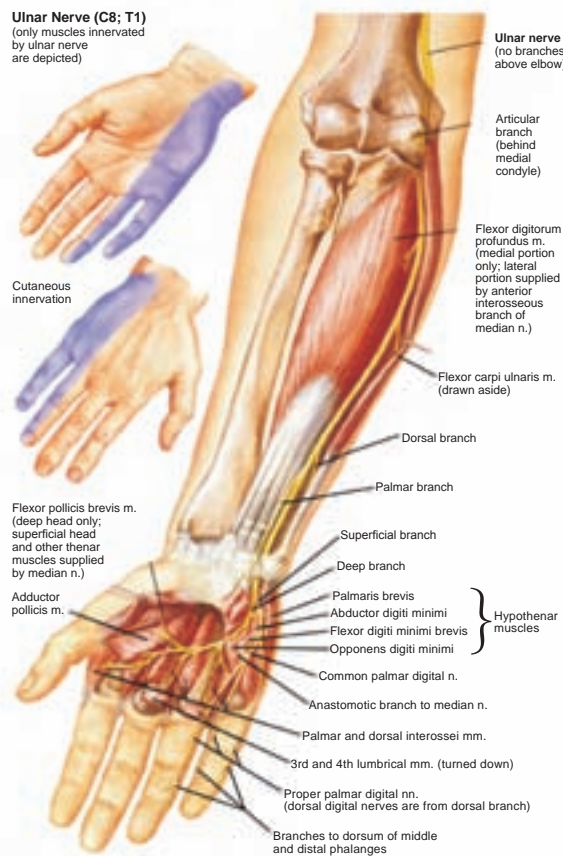


Differential diagnosis:

The most frequent differential diagnosis includes:

- C8/T1 radiculopathy
- Lower trunk/Medial cord brachial plexopathy
- Ulnar nerve lesion at the wrist
- Amyotrophic Lateral Sclerosis
- Multifocal Motor Neuropathy with conduction blocks

Ulnar Nerve (C8; T1)
(only muscles innervated by ulnar nerve are depicted)



ULNAR NERVE (C8; T1)

(Only muscles innervated by ulnar nerve are depicted)

Treatment:

After establishing the correct diagnosis and excluding other conditions in differential diagnosis, a conservative approach may be attempted in milder cases. This includes avoiding further pressure on the nerve, use of elbow pads, and the use of night elbow splints. Steroid injections to the cubital tunnel do not improve the function beyond that observed with splints. Surgical intervention with decompression of the cubital tunnel may be considered in more severe cases. Several surgical techniques are available and the choice of technique should be selected by the surgeon.

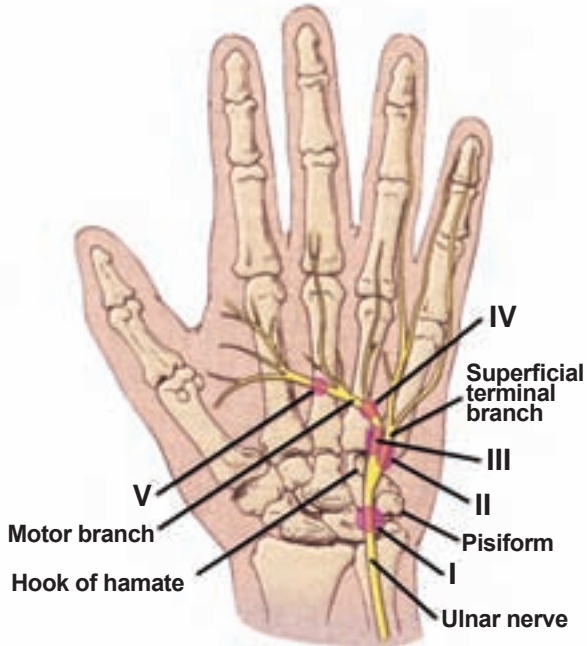
CAPE COD
6 Main Street
Hyannis, MA 02601
Tel: 508-775-2600

DRASKO SIMOVIC, M.D.
Board Certified in: Neurology, Clinical Neurophysiology,
Electrodiagnostic Medicine, Disability Analysis

LAWRENCE
50 Prospect Street #404
Lawrence, MA 01841
Tel: 978-687-2586

ULNAR HAND

(Ulnar entrapment at the wrist)



Ulnar entrapment at the wrist

Etiology:

- Extrinsic trauma
- Ganglion cysts
- Tumors
- Aberrant Artery
- Idiopathic

Symptomatology:

Patients may complain of wrist pain, intrinsic hand muscle weakness and atrophy, with or without sensory symptoms depending on the exact site of lesion. Wu and colleagues classified the lesion into five types:

- **Type I:** The lesion is proximal or within Guyon's canal, with intrinsic muscles weakness and with sensory symptoms in the ulnar innervated fingers, but with sparing of the dorsum of the hand, as dorsal ulnar cutaneous nerve branches off proximal to the wrist.
- **Type II:** The lesion is in Guyon's canal, affecting only the superficial sensory branch, leading to sensory disturbance which is limited to the fourth and fifth fingers, with sparing of the dorsum of the hand and the palmar cutaneous distribution.
- **Type III:** The lesion is in Guyon's canal, distal to the superficial sensory branch, leading to a pure motor nerve lesion, with weakness of all intrinsic hand muscle.
- **Type IV:** The lesion is in Guyon's canal, distal to the deep motor branch for hypothenar muscles, leading to weakness of the intrinsic hand muscles, excluding the hypothenar muscles.
- **Type V:** The lesion is the most distal variety of pure motor lesions, with weakness being limited to the first dorsal interosseous and adductor pollicis muscles.

Electrodiagnostic studies:


The electrophysiologic findings vary, depending of the site of the lesion. Nerve conduction techniques with recording from the abductor digiti minimi and first dorsal interosseous may assist in localizing the lesion and excluding alternative diagnosis.

Other studies:

Plain X-ray and CT may exclude pisiform and hook of the hamate fractures. When history reveals more insidious onset with no trauma, a MRI is indicated in a search of a ganglion cyst or other mass lesions.

Treatment:

In mild trauma cases, a conservative approach is indicated while for more severe cases or when a mass lesion is found, a surgical exploration is indicated.



ELECTRODIAGNOSTICS:

Ulnar Motor Nerve Conduction Study

Newsletter courtesy of:

EMG Laboratory
Drasko Simovic, M.D.

Lawrence: 978-687-2486
Hyannis: 978-775-2600

www.emglaboratory.com

Comments or suggestions?
info@emglaboratory.com

Literature:

- Kimura J. in: *Electrodiagnosis in Diseases of Nerve and Muscle*
Daube J. in: *Clinical Neurophysiology*
Brown W., Bolton C. and Aminoff M. in: *Neuromuscular Function and Disease*
Mendel J., Kissel J. and Cornblath D. in: *Diagnosis and Management of Peripheral Nerve Disorders*